

Common problems in well term neonates  
On postnatal ward

<b>Key Document code:</b>	WAHT-KD-015
<b>Key Documents Owner:</b>	Dr Vivianna Weckemann   Consultant Paediatrician
<b>Approved by:</b>	Paediatric Quality Improvement Meeting
<b>Date of Approval:</b>	2 <sup>nd</sup> August 2019
<b>Date of Review:</b> <b>This is the most current version and should be used until a revised document is in place</b>	2 <sup>nd</sup> August 2022

Key Amendments

Date	Amendments	Approved by

**Introduction**

This guideline highlights some common conditions Junior Paediatric staff may encounter on the postnatal ward. It is designed to aid assessment and management. It is not an exhaustive list and is not a replacement for the clinician's judgement, but differentiates conditions which need urgent action and Senior Review from those which settle without intervention.

Paediatric staff should familiarise themselves with the separate guidelines which are available on the intranet for the following conditions:

- Asymptomatic Heart Murmurs detected on postnatal wards
- Reducing risk of Neonatal Group B Streptococcal (GBS) Infection
- Babies born to Hepatitis B Carrier Mothers
- Management of infants born to HIV Positive Mothers
- Lumbosacral skin lesions in neonates
- Management of excessive weight loss and prevention of hypernatraemic dehydration in breast fed babies
- Management of Polycythaemia
- Neonatal BCG Vaccination Policy
- Pharmacological Pain relief on the Neonatal Unit
- Phototherapy for jaundice on the Neonatal Unit
- Tongue Tie in Breast Feeding (Ankyloglossia)
- Babies 'At Risk' of Hypoglycaemia
- Treatment of accessory digits and facial skin tags in newborns
- Hip examination in the Newborn
- Suspected Down's Syndrome

**Common Problems**  
**Antenatal Diagnosis**

Please note that the key documents are not designed to be printed, but to be used on-line. This is to ensure that the correct and most up-to-date version is being used. If, in exceptional circumstances, you need to print a copy, please note that the information will only be valid for 24 hours and should be read in conjunction with the key document supporting information and/or Key Document intranet page, which will provide approval and review information.

**WAHT-KD-015**  
**Neonatal Key Documents**

**Antenatal Hydronephrosis**

This may be related to an underlying renal tract abnormality. Follow the table below (also found on the small laminated cards):

<b>Antenatal Hydronephrosis</b>			
Unilateral/ Bilateral	AP diameter of Renal Pelvis	Calyces Dilated?	Action for SHO
Unilateral	≤ 7 mm	No	Nil, normal kidneys
		Yes	Trimethoprim 2mg/kg nocte USS at 6 weeks Baby Clinic at 8 weeks
	> 7 mm	No	
		Yes	Trimethoprim 2mg/kg nocte USS at 4-14 days Baby Clinic at 4 weeks
Bilateral	> 7 ≤12 mm	Yes or No	Consultant review and USS prior to discharge
	> 12 mm	Yes or No	
	Both ≤ 7 mm	Treat as for Unilateral Dilatation	

*Nb: When applying the above advice, if there is no mention of Calyceal Dilatation in the ultrasound report, then it can be safely assumed the calyces are not dilated.*

**Antenatal Ultrasound Findings which are ‘Soft Markers’**

There are many findings on Antenatal Ultrasound scan which are classed as ‘soft markers’ for the foetus having a chromosomal abnormality or other disease, including Echogenic Bowel, Cardiac Echogenic Foci, and Short Femurs. These should have been fully investigated and explained to the parents antenatally. Alternatively they should have been referred to the Paediatricians via an Antenatal Paediatric Referral Form, and a clear action plan outlined antenatally. If this is not the case then discuss with the Duty Consultant.

**Face/Skull Problems**

**Local Swelling**

Caput Succadeneum is a swelling over the presenting part of the head caused by local oedema due to intrapartum localised pressure. It requires no treatment and generally subsides over the next 2-3 days.

Chignon is very localised swelling and caused by the suction cap during ventouse extraction. Again this needs no treatment and resolves over the following few days.

Cephalhaematoma is a collection of blood between periosteum and skull bone. It is felt as a soft swelling over the affected bone (most commonly the parietal). They are distinguished from other causes of head swelling by the fact that they do not extend across suture lines. They are benign in nature. They may take a significant time to resolve (sometimes in excess of 6 weeks), and can become progressively harder over time due to calcification. It is often useful to let parents know that these babies are more likely to develop jaundice. Parents should be reassured as they resolve spontaneously and require no treatment.

**WAHT-KD-015**  
**Neonatal Key Documents****Fontanelles and Sutures**

The anterior fontanelle is variable in size in newborn babies. There is no recognised lower limit of normal (providing it is patent), and the generally accepted upper limit of normal is 4cm x 4cm at its widest points. Bulging may indicate raised intracranial pressure.

The suture lines should be palpated. Separation is abnormal and may indicate raised intracranial pressure. Overriding of the bones of the vault is common in the first 48 hours (giving a rise to a 'step up' feel), but ridging of the suture lines implies craniosynostosis (premature fusion of the sutures), especially if the head shape is abnormal. If this is felt to be the case arrange senior review.

**Epstein's Pearls**

These are white papules found on the oral mucosa (palate or gums, usually at the junction of the hard and soft palate). They are normal.

**Preauricular Tags and Pits**

If a preauricular skin tag or pit is found then other abnormalities should be sought in the course of the normal newborn examination. Latest evidence suggests that in the absence of any other abnormality, there is no need to investigate these children any further. If the parents wish to have a skin tag excised they should be referred as per the separate guideline available on the hospital intranet.

**Eye Problems****Sticky eyes**

A mucoid discharge is very common after birth. If persistent it is most likely to be due to failure of canalisation of the nasolacrimal duct. A membranous obstruction persists in this structure in 70% of those neonates who have discharge. This resolves spontaneously by 3 months of age in 70%, and by 1 year in 99%. Simple hygiene with cleaning of crusts using sterile water and cotton wool is the best treatment for this condition.

If there is evidence of red conjunctiva, lid swelling, or excessive pus discharge suggestive of conjunctivitis, then a swab should be sent for culture and sensitivity (and consideration given to chlamydial swabs, especially if conjunctivitis is bilateral), and chloroamphenicol ointment should be commenced pending culture results. It is the responsibility of the requesting doctor to ensure this result is communicated to the child's parents and GP.

**Lack of Red Reflex**

Congenital Cataract is the most common form of preventable childhood blindness, and should be suspected if unable to elicit a red reflex during examination (NB this is often more difficult in Non-Caucasian babies). Any child with an absent Red Reflex should therefore be reviewed by a Registrar, with a low threshold for referral to Ophthalmology.

**Squint**

A third of newborns have an intermittent exotropia (outward eye deviation), but esotropia (inward eye deviation) is not normal. This must also be differentiated from 'pseudosquint' (appearance of squint caused by facial features, but with no true squint). The appearance of pseudosquint will disappear over time, If there are concerns these children should be discussed with the duty consultant, and referred to Ophthalmology if felt to be necessary.

**WAHT-KD-015**  
**Neonatal Key Documents****Subconjunctival Haemorrhage**

These are very common after birth (in those babies delivered vaginally) and are harmless. They fade over the course of the first week.

**Umbilical Problems**

At birth the midwife puts a plastic clip on the umbilical cord and cuts the cord. It is then left until the cord falls off a few days later.

**Umbilical Hernias**

Umbilical hernias are managed conservatively, as they are very unlikely to incarcerate. Only large defects still present at 1-2 years of age are operated upon. Follow up with GP.

**Umbilical Granuloma**

Granulomatous lesions can occur over the necrotic area of the umbilical stump. If confident of the diagnosis they can be treated with chlorhexidine powder or silver nitrate. Arrange Registrar review if there is doubt regarding the diagnosis.

**Umbilical Flare**

Umbilical stumps are often described as moist or smelly. This can raise concerns about umbilical infection. The important discriminating factor is the condition of the periumbilical skin. If there is any sign of flare, i.e. cellulitis – usually at the superior pole of the cord, then the baby needs to be treated with intravenous flucloxacillin and gentamicin pending culture results from umbilical swabs and blood cultures. If there is no evidence of cellulitis then it is appropriate to treat with regular hygiene and chlorhexidine powder providing the baby remains clinically well.

**Skin Problems****Milia**

These are multiple white cysts 1mm in diameter, commonly seen on the nose or cheeks. They require no treatment.

**Erythema Toxicum**

This is a very common maculopapular rash occurring between day one and three of life. Lesions are approximately 5mm in size and consist of a small yellow pustule centre and a blotchy erythematous surround. It settles spontaneously within one week.

**Mongolian Blue Spots**

These occur in 90% of non Caucasian neonates and need no intervention. They are blue-grey macular areas most commonly found on the lumbo-sacral area and buttocks. If elevated, they should be reviewed by a Registrar.

**‘Cyanosis’**

Medical staff are often asked to review babies due to blueness, either of their face or extremities. This is often fixed, as opposed to ‘dusky episodes’, which are intermittent in nature.

In the first 48 hours the most common cause of blueness of the hands and feet is simple acrocyanosis- literally ‘peripheral cyanosis’. This is a normal finding in a baby who is otherwise well. However, in order to confirm that this is the cause, oxygen saturations should be checked.

## WAHT-KD-015 Neonatal Key Documents

Another common finding is 'facial congestion'. This is a purple/bluish discolouration of the face, and is usually accompanied by a facial petechial rash. This is most usually seen following a rapid delivery. Again this is a normal finding in a baby who is otherwise well and is pink centrally. Oxygen saturations should be checked to confirm that this is the case.

Central Cyanosis is never normal and requires urgent senior review and further investigation.

### Single Palmar Crease

These are present in 5% of the population. In the absence of any other clinical findings they are of no significance and require no further investigation.

### Vomiting

#### Bilious

Bilious vomiting is indicative of surgical pathology until proven otherwise. Signs and symptoms of bowel obstruction should be sought. All such cases should be discussed with a Registrar urgently.

#### Altered Blood

Some babies swallow a significant amount of their mother's blood at or before delivery, especially if the mother has had an antepartum haemorrhage. They can then vomit brown altered blood and also pass altered blood in their bowel motions. This needs no intervention.

The other most common cause of bloody vomitus is secondary to swallowing blood from cracked nipples in breast fed babies. Again this needs no intervention provided the baby is otherwise entirely well.

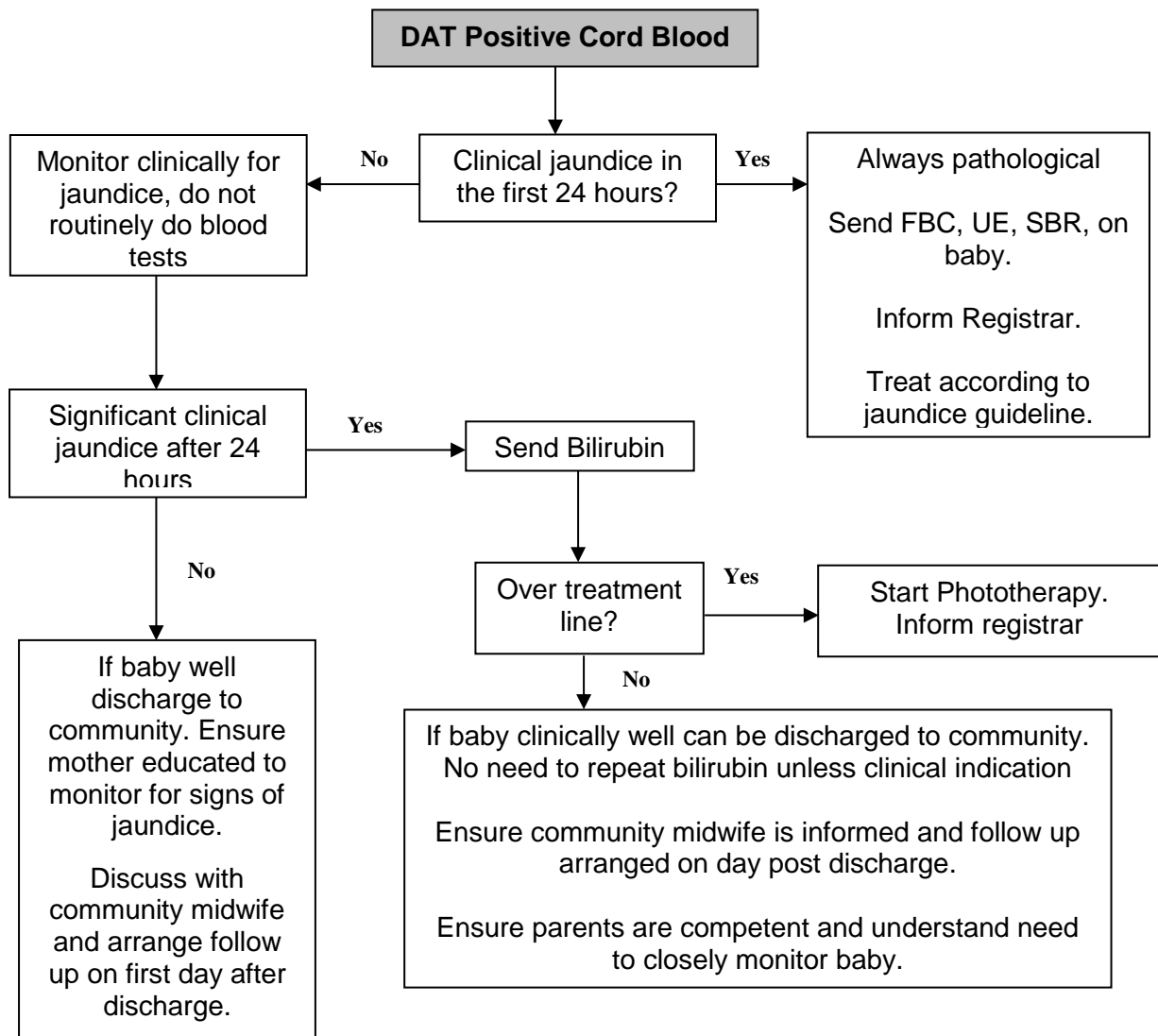
### Haematological Problems

#### Direct Coombs Test

Direct Coombs Tests (DCT) or Direct Antiglobulin Tests (DAT) are used to detect immune mediated destruction of red blood cells. A positive DAT suggests that there is an incompatibility between the fetal and maternal red blood cells and increases the possibility of haemolytic disease of the newborn. This manifests clinically as jaundice.

Babies born to Rhesus negative women have their cord blood sent to Blood Bank by midwife staff for DAT and Blood Group Analysis. The result can be looked up on the pathology reporting system under Mother's surname and 'cord' as the first name. Remember that Anti-D prophylaxis given to women during their pregnancy can give a weakly positive DAT.

There is no evidence to suggest the best management of DAT positive babies for detection of haemolytic disease. The following flow chart suggests one strategy. We do not prescribe folic acid routinely.



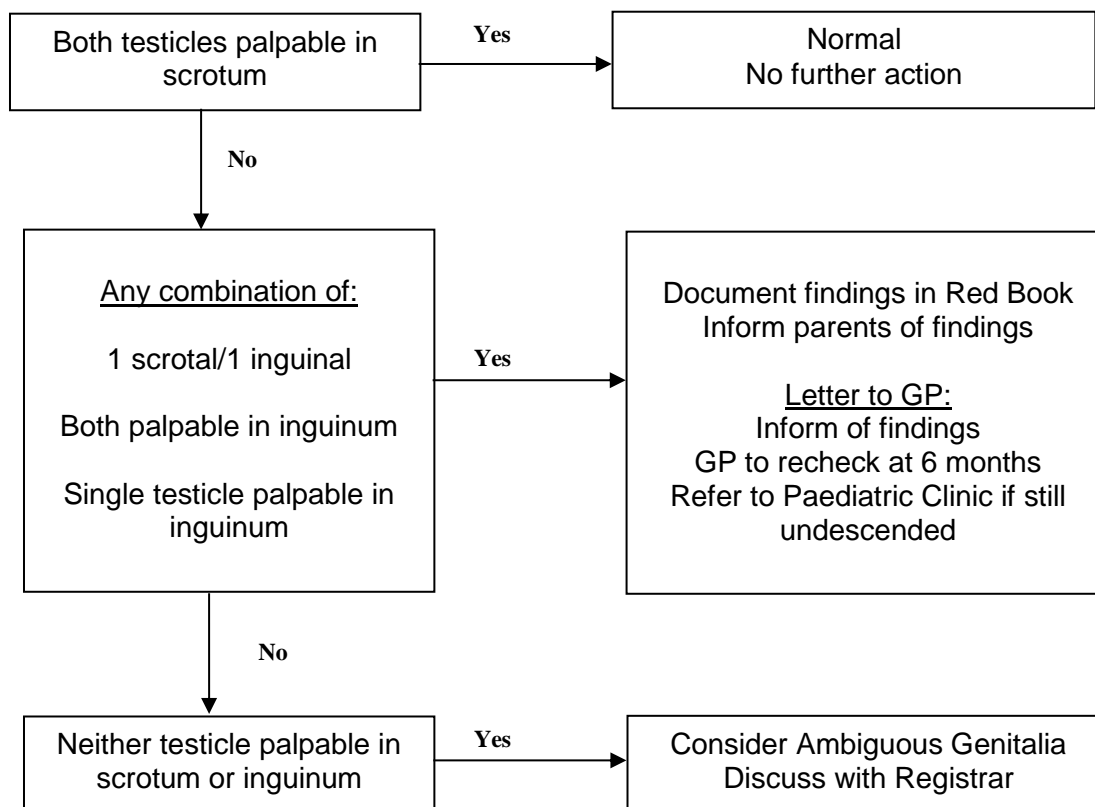
**Follow Up**

If baby requires phototherapy following Positive DAT the SHO should arrange follow up in Children's Clinic at 2 weeks of age for repeat FBC. Split bilirubin should also be repeated if still jaundiced. On arranging follow up it should be made clear in Clinic Diary that baby is attending due to a Positive DAT. Blood forms should be filled out prior to discharge by SHO, and results should go to baby's Consultant Paediatrician. Clinic Nurses will take appropriate blood samples and chase up results later that day. If haemoglobin <9g/dl Registrar should be informed that day. Further follow up should be arranged by Registrar or Consultant.

## Problems in the Nappy Area

### *Impalpable and Undescended Testes*

If a testis is palpable in the scrotum, note first scrotal size and examine the inguinal canal



### Delay in Passing Urine

Junior staff are often asked to review babies due to failure to pass urine by 24 hours of age. Most commonly babies will have passed urine immediately after birth, and then will pass very little urine in the next 24-36 hours, especially if breastfed. Passage of urine is more difficult to detect with concurrent meconium passage, and also due to the fact that modern nappies are extremely absorbent. As long as there has been an Antenatal Ultrasound Scan showing 2 normal sized kidneys then no action is required. Do not keep the baby in hospital to await passage of urine.

### 'Blood' in the nappy

Most commonly this is due to 'salmon pink' urate crystal from the baby's urine. This settles spontaneously and needs no intervention. Genuine macroscopic haematuria or PR bleeding should always be presumed to be pathological and requires investigation. Vaginal bleeding is commonly due to oestrogen withdrawal, and requires no intervention. It should stop within 2-3 days. Advise parents to monitor, and see their GP if it does not stop.

### Vaginal Skin Tags

These are most commonly due to relative hymenal hypertrophy providing the genitalia are otherwise normal. They become less noticeable over time as the child grows. They need no treatment. Parents should be reassured.

### **Hydrocoele**

Hydrocoeles generally resolve spontaneously and do not require treatment. These can be followed up by the GP at routine appointments.

### **Inguinal Herniae**

Inguinal herniae are not uncommon in neonates, especially preterm infants. They are often easily reducible, though are at risk of becoming incarcerated. Outpatient review should be arranged by referring to the On Call Consultant Surgeon in BCH after discussion with the local Duty Consultant Paediatrician. They should be referred by fax and letter. Phone the relevant secretary to ensure the letter has been received. When discharging, advise the parents of the signs of incarceration and strangulation.

### **Hypospadias**

This is the proximal placement of the urethral meatus along the ventral surface of the penis or perineum. Refer by letter for Outpatient review to a Paediatric Urologist in BCH. Make sure to tell the parents not to proceed to circumcision until they have seen the urologist as foreskin may be used in the operation. Ensure that both testes can be felt in the scrotum, and if there is doubt organise senior review.

### **Limb Problems**

#### **Talipes Equinovarus**

This is one of the most common neonatal orthopaedic problems with a prevalence of 1 per 1000 live births. The goal of treatment is clinical and x-ray correction. There is a wide spectrum of severity. If there is an equinovarus position, without using undue force an attempt should be made to overcorrect it by abduction and dorsiflexion of the foot and ankle so that the little toe touches the outside of the leg (in term babies). If this manoeuvre is successful no treatment is indicated (though parents may wish to continue to manipulate the foot during nappy changes), but deformities that cannot be so corrected are classified as 'true' talipes equinovarus and should be referred for orthopaedic assessment. These babies should not be referred to the local physiotherapy services.

Orthopaedic referral is made by letter to Mr Bache at BCH with an initial copy faxed to 0121 333 8081. Remember to send a copy to the GP. It is prudent to ring Mr Bache's secretary 0121 333 8099 during working hours to ensure that the fax has arrived safely.

#### **Writing Referral Letters**

When referring a child to another hospital it is best if the letter is dictated and then typed by our Paediatric Secretaries. If, however, it seems more efficient to type the letter yourself feel free to do so. This letter must include:

- Full patient details
- WRH Consultant
- Accepting Consultant, Specialty and Hospital

This letter should then be emailed to the secretary of the Duty Consultant for formatting and storage.



*References*

- Rennie C (2005) *Robertson's Textbook of Neonatology, Fourth Edition, Elsevier Churchill Livingstone.*
- Stephenson T (2000) *Pocket neonatology, Churchill Livingstone.*
- *Robertson C (1996) A manual of normal neonatal care, 2<sup>nd</sup> edition. Arnold.*