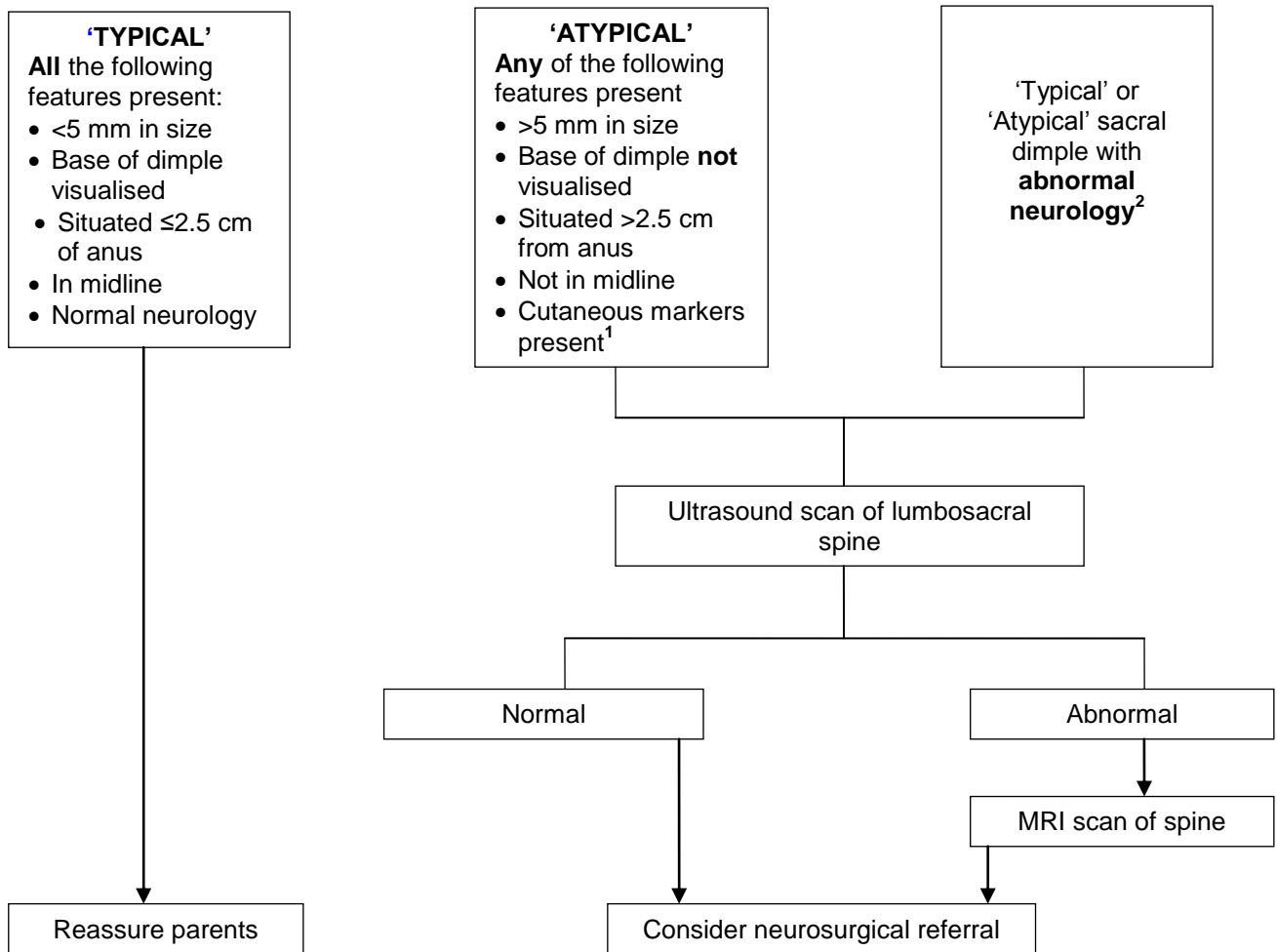


SACRAL DIMPLE



Notes

1. **Cutaneous markers** e.g. dermal sinus, pigmentation, hairy patch, abnormal skin texture, lipoma, cyst, skin tag, haemangioma and swelling; can be seen in isolation or any combination
2. Check for neurological signs in lower limbs – leg movements, tone, deep tendon reflexes, presence of patulous anus etc.